

Accuracy of interpretation of nasogastric tube position on chest radiographs by diagnostic radiographers: A multi-case, multi-reader study



A. Creeden ^a, S. McFadden ^b, C. Rainey ^b, S. Campbell ^c, S. Ather ^{d, e}, A. Hajilou ^c, R. Bond ^f, P. McAllister ^f, N. Woznitza ^{g, h, *}

^a Imaging Department, University Hospitals of Leicester NHS Trust, UK

^b School of Health Sciences, Ulster University, UK

^c East Kent Hospitals University NHS Foundation Trust, UK

^d Oxford University Hospitals NHS Foundation Trust, UK

^e RAIQC Ltd., UK

^f School of Computing, Ulster University, UK

^g University College London Hospitals NHS Trust, London, UK

^h Canterbury Christchurch University, Canterbury, UK

ARTICLE INFO

Article history:

Received 12 August 2024

Received in revised form

4 October 2024

Accepted 23 October 2024

Keywords:

Nasogastric tube

Radiograph

Chest x-ray

Radiographer

Reader performance

Accuracy

ABSTRACT

Introduction: Feeding via a misplaced nasogastric tube (NGT) is a common but preventable cause of patient harm. The aim of this study was to determine the accuracy of diagnostic radiographers' assessment of NGT position on chest radiographs (CXR) and safe-to-feed decisions.

Methods: A multi-case, multi-reader study was conducted using an online image interpretation platform. A test bank consisting of 15 CXRs with an NGT in-situ was created. Diagnostic radiographers without formal qualifications in CXR interpretation were recruited via two international conferences. Participants placed an electronic marker on each CXR to identify the location of the tip of the NGT and indicated whether or not they believed that the tube was safely positioned.

Results: 68 participants were recruited. Each participant reviewed 15 CXRs, providing 1020 unique image assessments. 76 % (n = 778/1020) image assessments were completely correct (both the position of the tip of the NGT was accurately located and an appropriate safe-to-use decision made). In 5 % (n = 56/1020) of cases the NGT was safely positioned and the location of the tip was correctly identified by the participant but the tube was erroneously determined to be unsafe for feeding. In a further 6 % (n = 59/1020) of cases the participant correctly located the tip of an NGT in an unsafe position but indicated that the tube was safe to use. Participants failed to correctly identify the tip of the NGT in the remaining 12 % (n = 127/1020) of cases.

Conclusion: Consistent with previous studies involving other staff groups, diagnostic radiographers without formal qualification in CXR interpretation can assess NGT positioning on radiographs with moderate accuracy but require further training, including strategies for the identification of poorly-visualised tube tips, to achieve the 100 % accuracy necessary for this safety-critical task.

Implications for practice: A bespoke training programme which includes teaching on image quality, tube tip identification and assessment of tube positioning using the National Patient Safety Agency (NPSA) four criteria, should be delivered prior to implementation of a radiographer-led NGT CXR evaluation service.

© 2024 The Author(s). Published by Elsevier Ltd on behalf of The College of Radiographers. This is an open access article under the CC BY license (<http://creativecommons.org/licenses/by/4.0/>).

Introduction

Nasogastric tubes (NGTs) are a frequent intervention in patients who are unable to eat or drink by mouth, with approximately one million purchased for use in the United Kingdom National Health Service (NHS) every year.¹ They are inserted through a nostril and

* Corresponding author. School of Allied and Public Health Professions, Faculty of Medicine, Health and Social Care, Canterbury Christchurch University, Canterbury, UK.

E-mail address: nicholas.woznitza@nhs.net (N. Woznitza).

down the oesophagus into the stomach but in up to 4% of cases the tube may inadvertently enter the lung.^{2,3} Alternatively, the tip of the NGT may be insufficiently advanced and consequently positioned within the pharynx or oesophagus. Confirmation of tube position is critical to patient safety; feeding a patient via a misplaced NGT can result in aspiration pneumonitis, potentially leading to severe patient harm or death. Assessment of the acidity or alkalinity of tube aspirate is the first line investigation for assessing NGT tip position. A chest radiograph (CXR) is recommended if a tube aspirate cannot be obtained or if the pH reading of the aspirate is greater than 5.5.⁴

Misplacement of an NGT into the respiratory tract, which is not detected prior to starting a feed, is considered to be a “Never Event”.⁵ “Never Events” are defined by NHS England as “Serious Incidents that are entirely preventable because guidance or safety recommendations providing strong systemic protective barriers are available at a national level, and should have been implemented by all healthcare providers.”⁵ Safety systems introduced to prevent NGT “Never Events” must not rely on radiographic confirmation of position unless it can be shown that all involved personnel have the requisite skills.⁶ Unfortunately these incidents continue to occur despite multiple alerts and local systems being implemented.^{7,8,9}

In the future artificial intelligence (AI) assessment of NGT positioning may become increasingly accurate and widespread, but is not expected to replace the role of the trained observer in the foreseeable future.¹⁰ The accepted gold standard interpretation of CXR for confirmation of NGT placement is a clinical report provided by a radiologist or reporting radiographer. Currently, however, due to the frequency of NGT use and timing of insertion, the responsibility for clinical evaluation of NGT placement-check radiographs is not-uncommonly delegated to the referring clinical team.¹ Relatively modest levels of competence in NGT CXR interpretation have been identified amongst junior medical staff^{11,12} and misinterpretation of radiographs by junior medical staff has been cited as a key cause of NGT incidents.¹³ A HealthService Investigation Branch (HSIB) report into NGT placement highlighted radiographic interpretation as a critical area of weakness in the healthcare system leading to patient harm¹ and this finding is supported by the most recent data on “Never Events”.⁹

There is a growing appreciation of the role that radiographers might play in reducing the frequency of “Never Events” related to misplaced NGTs.^{14,15,16,17} Following training radiographers are able to accurately and safely assess the position of NGTs on CXRs in both adult and paediatric patients.^{14,15,16} NHS England has commissioned the Royal College of Radiologists to implement the *NHS transformation plan to prevent misplaced NGT Never Events related to radiographic interpretation using a diagnostic radiographer-led approach*.¹⁸ Although NGT training packages have previously been developed,^{19,20} as part of this work it is proposed that a NGT training package for radiographers will be further developed, updated and refined.

A national roll-out of a diagnostic radiographer-led service would require a very large number of radiographers to undertake training and would involve a significant investment of staff time. This will be a particular issue in an already stretched workforce.^{21,22} Even in the absence of specific training, however, many diagnostic radiographers

may have extensive undergraduate knowledge and post-graduate experience of reviewing CXRs. The availability of data on radiographers’ current performance in evaluating NGT check CXRs might facilitate the development of a training package which fulfils the learning needs of radiographers more efficiently and effectively.

The aim of this study was to provide baseline data on the accuracy, prior to undergoing specific training, of radiographers’ assessment of NGT position on CXRs, and to highlight any associated training needs.

Method

Ethical approval for the study was granted by Canterbury Christchurch University Ethics Committee (ETH2223-0131, 2nd Feb 2023).

A multi-case, multi-reader study was conducted using an online image interpretation platform. A convenience sample of diagnostic radiographers attending the European Congress of Radiology 2023 (ECR, 1st – 5th March 2023) and the UK Imaging and Oncology Conference 2023 (UKIO, 5th – 7th June 2023) were recruited to the study via dedicated ‘Research Hubs’. Informed consent was obtained from all participants.

Demographic data were collected from diagnostic radiographer conference delegates who met the inclusion criteria (Table 1) via an online questionnaire available in the research hubs. Participants then used a computer workstation and the RAIQC clinical simulation platform (www.raiqc.com) to view a series of 15 anonymised CXRs from a validated image bank, each of which demonstrated a NGT in-situ. This series included correctly sited NGTs (n = 6) as well as NGT tips located in the oesophagus (n = 6) and the lungs (n = 3). The image set was independently viewed by each participant in a random order.

For each image, participants were required to complete two tasks:

1. Place an electronic marker to identify the location of the tip of the NGT on each image.
2. Indicate whether or not they believed that the NGT was safely positioned for feeding (safe-to-feed).

Participants were able to window and/or zoom images as required. No criteria for determining safe positioning of a NGT were provided to the participants. The participant’s review of the images typically lasted around 15 min but no time limit was enforced. Each participant undertook the image viewing session only once. On completion of the image viewing activity, participants were informed of their total score but did not receive detailed feedback. To encourage recruitment participants were offered entry to a raffle with a small prize, but inclusion in the raffle was optional.

Data analysis

Demographic details and accuracy data for the participants were summarised using descriptive statistics. Percentage accuracy was calculated for each participant and each image.

Table 1
Inclusion/exclusion criteria.

Inclusion	Exclusion
HCPC registered diagnostic radiographer (or equivalent if practising outside of the UK)	Therapeutic radiographer, student radiographer, assistant practitioner, radiology assistant, radiologist
Has practised as a radiographer/radiography educator in the last 6 months.	Post-graduate chest x-ray image interpretation qualification

Ground-truth regions of interest for the position of the tip of the NGT and ground-truth safe-to-feed decisions were determined via consensus review of two experienced radiologists.

To facilitate visual analysis a Python script was developed using Pandas library²³ in conjunction with Matplotlib²⁴ to plot the coordinates of the tip position identified by each participant for each image alongside the corresponding ground-truth tip locations. The accuracy of each participant's response was calculated using Shapely;²⁵ this library enabled the plotting of a polygonal shape on the coordinate plane to represent the ground-truth region. Each plot generated by the Python script included the ground truth region of interest coordinates (polygon shape), a marker representing the NGT tip position marked by the participant, annotations displaying the case number and participant ID, and a message stating whether the participants' response was correct or not. This visual analysis aided understanding of overall participant accuracy and identifying areas for improvement in training.

Results

The study recruited 68 conference delegates (33 at ECR, 35 at UKIO). Participants had a wide range of post-qualification experience (Table 2). Most of the participants (n = 62) had experience of projectional (plain film) radiography, and this was the primary area of practice for just over a quarter (n = 19; Table 3). Participants were employed in public hospitals (n = 40), academic institutions (n = 25) or private practice (n = 3). The majority of participants were practising in the UK (n = 46), but a wide range of countries were represented within the sample (Table 4).

Participants marked on each CXR their perceived location of the tip of the NGT and indicated whether they considered the NGT was safe-to-feed (Fig. 1). Each participant reviewed 15 CXRs, generating a total of 1020 unique image assessments.

Approximately three quarters (76 %, n = 778/1020) of image assessments were completely correct (both the position of the tip of the tube was identified accurately and an appropriate safe-to-feed decision made). Participants were more likely to identify incorrect NGT placement when the tip of NGT was in the lung, and less likely when the tube was in the oesophagus (Table 5).

Individual participants made correct assessments for between 5 and 15 of the images. The mode was 13 correct assessments, and 4 % (n = 3) of participants achieved a maximum score by accurately identifying the NGT tube tip and making a correct safe-to-feed decision for all 15 images. The sample size was too small to perform reliable sub-group analysis but visual inspection of the data indicates that there were no clear associations between accuracy and experience, primary modality, employment type or country of practice.

There were three cases where all of the participants unanimously agreed with the reference standard. Incorrect identification of NGT tip position occurred in 12.4 % (n = 127/1020) of the unique image assessments. The most frequent mis-identifications occurred on images where the NGT tip was not optimally visualised and

Table 3
Primary area of practice of participants.

Primary area of practice	No. of participants
Education	21
Projectional (plain film) radiography	19
MRI	9
CT	5
Fluoroscopy/intervention	3
Ultrasound	3
Other	3
Research	2
Breast imaging	1
MSK reporting	1
Nuclear medicine	1
Total	68

Table 4
Country of practice of participants.

Country of practice	No. of participants
United Kingdom	46
Malta	8
Ireland	5
Denmark	2
Portugal	2
Belgium	1
Germany	1
Hong Kong	1
Italy	1
Switzerland	1
Total	68

required extensive windowing; in the majority of these cases the location marked was along the line of the tube but proximal to the tip. Other less common errors included marking the tip of the NGT guidewire rather than the tip of the tube itself, or mistaking a co-existing endotracheal tube for the NGT.

The NGT was safely positioned for 408 image assessments. In 13.7 % (n = 56/408) of these assessments the participant correctly identified the position of the tip within the stomach, but erroneously determined the tube to be unsafe for feeding. The NGT was in an unsafe position for feeding for 612 image assessments. Participants correctly located the tip of the NGT in an unsafe position (either the oesophagus or the lung) but subsequently indicated that the tube was safe-to-feed in 9.6 % (n = 59/612) of these cases; overwhelmingly this occurred for images where the tip of the tube was in fact located within the oesophagus (n = 51/59).

The NGT tip was projected over the lung in 3 of the 15 images in the test series, providing 204 opportunities for participants to identify a pulmonary-placed NGT. In 99 % (n = 203/204) of these unique image assessments the location of the tip of the NGT was correctly identified by the participant but, despite this, 3 % (n = 7/204) of the pulmonary-sited NGTs were incorrectly deemed to be safe-for-feeding.

Discussion

The current study is the first evaluation of the ability of an international cohort of diagnostic radiographers to assess NGT position on CXRs. The participants in this study were able to identify NGT positions and make appropriate decisions regarding safety for use in the majority of cases (76 %, n = 778/1020), broadly consistent with junior emergency medicine physicians (79 %, n = 266/335)²⁶ but below the 100 % accuracy required for this safety-critical task. Performance was also below the 98.5 % (n = 4383/4449) accuracy achieved in a clinical audit of radiographers who had received

Table 2
Experience of participants.

Experience (years)	No. of participants
0–4	11
5–9	7
10–14	17
15–19	13
20+	20
Total	68

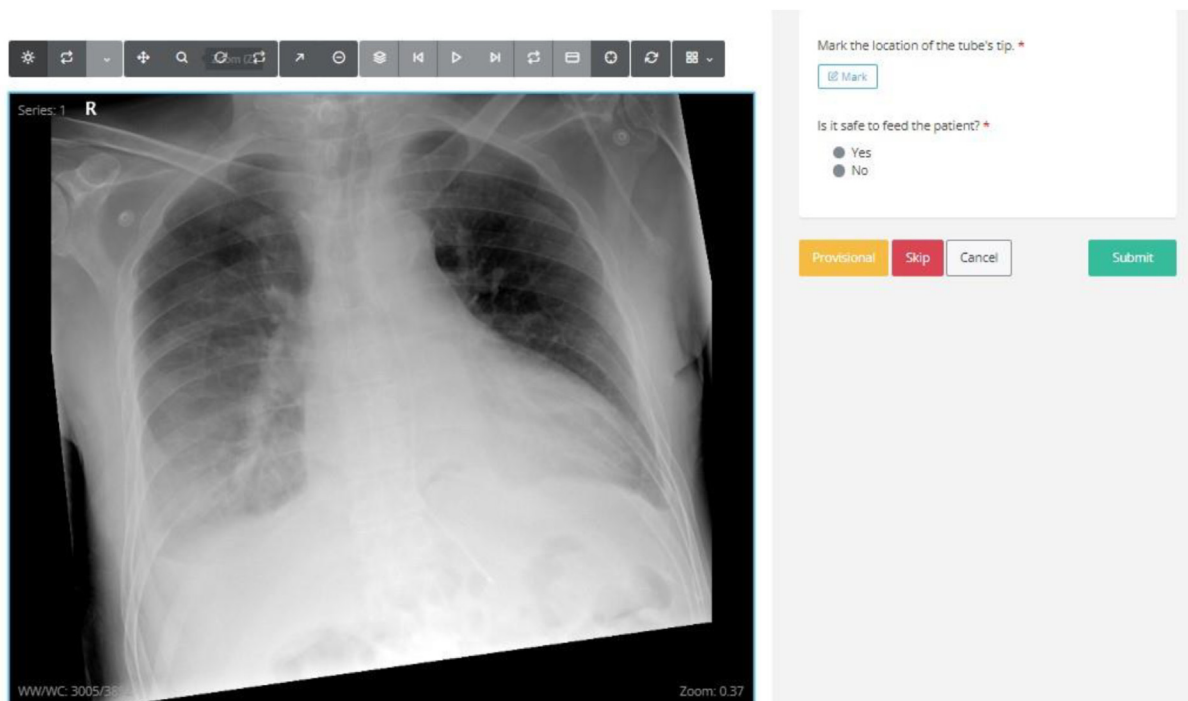


Figure 1. Collection of tube tip location and safe-to-feed responses via the RAIQC platform.

Table 5 Participant responses (numbers in brackets indicate percentage of row total).

Actual location of tube tip	No. of cases	No. of participant responses	Tip location correct	Safe-to-feed decision correct	Tube position and safe-to-feed decision correct
Stomach	6	408	360 (88 %)	325 (80 %)	304 (74 %)
Oesophagus	6	408	330 (81 %)	347 (85 %)	278 (68 %)
Lung	3	204	203 (99 %)	197 (97 %)	196 (96 %)
Total	15	1020	893 (87 %)	869 (85 %)	778 (76 %)

bespoke training on NGT assessment,¹⁶ although the images assessed in the current study may have been more challenging than those encountered in the audit. In line with the current study, however, few participants in evaluations of medical students²⁷ and residents²⁸ made correct safe-to-feed decisions for all cases.

The majority of participating radiographers were able to reliably identify the NGT, even in the presence of other lines and tubes. In many cases where an error was made, the participant had marked a position along the line of the tube but proximal to its tip. This occurred most commonly on images where the tip was not optimally demonstrated. These findings support the concerns of previous authors regarding image quality of radiographs for NGT visualisation, which is not always optimal in clinical practice.^{29,30,31,32,33} Good radiographic technique and the use of line-enhancement software tools, where available, will mitigate the risk of interpretation errors, regardless of the professional background of the individual evaluating the tube position.

Participants correctly identified the tip of the tube, but subsequently made an incorrect decision regarding the suitability of the position of the tube for feeding in 11.2 % (n = 115/1020) of cases. These errors were relatively evenly split between describing a correctly sited tube as unsafe, and indicating that an unsafe tube was safe to feed. Both of these errors are known to occur in clinical practice; an audit of 1934 NGT CXRs identified 10 radiologist reports in which a NGT deemed unsafe by the researchers was described as safe (all <10 cm from the gastro-oesophageal junction), and 5 which erroneously advised removal of an appropriately

placed NGT.³³ Similar errors were also identified in a clinical audit of radiographers following bespoke training; 30 false negative and 36 false positive errors were identified from a sample of 4449 examinations.¹⁶ Any radiographer training package should, therefore, include clear instruction on the four criteria for safe NGT placement originally described by the NPSA (i.e. the NGT must follow the path of the oesophagus bisecting the heads of clavicles, bisect the bronchi at the carina, remain in the midline at level of diaphragm and deviate to the left below the diaphragm).³⁴

In keeping with a previous studies involving trained radiographers¹⁶ and medical students,²⁷ participants in the current study found it particularly difficult to distinguish between NGT tips in the distal oesophagus and those in the stomach. Where NGTs were erroneously identified as safe to feed, the tips of the tubes were most commonly located too proximal in the digestive tract, thereby increasing the risk of aspiration of feed. In clinical practice radiographers may also find difficulty interpreting nasogastric tube tips located within a hiatus hernia,^{35,36} although no examples were included in the current study.

For images where the NGT was positioned within the lung, it was incorrectly deemed safe-to-feed by the participant in 3 % (n = 7/204) of cases. In the clinical setting this would be considered a “Never Event” and could have fatal consequences. Whilst the frequency of this type of error in the current study is lower than that identified in a study involving junior emergency medicine physicians (4 %, n = 5/125)²⁶ it is nevertheless concerning, and notably higher than the 0.1 % error rate identified in a previous study of medical students²⁴

and 0 % in an audit of clinical practice in which radiographers who had undergone a bespoke training course.¹⁶

The results of the current study provide evidence that, for a radiographer-led NGT radiographic interpretation service to be safe and effective, investment in staff training is required. A standalone training programme can improve confidence,^{11,15} knowledge¹¹ and performance²⁷ in interpreting NGT positioning check radiographs but no nationally or internationally accepted and uniform training package exists.⁶ A bespoke training package which specifically meets the needs of radiographers should therefore be devised. On the basis of this study, it is recommended that the training should include:

- reinforcement of the importance of good image quality for accurate interpretation, particularly in the context of mobile radiographs in the ward environment
- instruction on the use of image manipulation tools such as contrast and brightness in order to improve tube visualisation
- guidance on the application of the NPSA four criteria for safe NGT placement³⁴

This study has a number of limitations. Firstly, a relatively small sample of conference delegates were recruited, whose knowledge, skills and experience may not be representative of the wider population of radiographers. Projectional radiography was the primary area of practice for 30 % of the participants in this study, and therefore the results may not be fully generalisable to clinical practice. It was noted however that participants' clinical experience and specialty were not obviously correlated with accuracy. Secondly, where radiographers are uncertain in clinical practice it would be expected that they seek advice from colleagues, but this option was not available to the study participants. Thirdly, viewing conditions in the conference Research Hubs were not optimised for image reporting. This, however, likely reflects the conditions in which radiographers would evaluate NGT radiographs in practice. Finally, performance of observers in retrospective laboratory experiments can be significantly worse than their performance in the clinical environment.³⁷ All limitations mentioned may have led to an underestimation of participants' clinical performance in this study.

Conclusion

Diagnostic radiographers without formal qualifications in chest reporting assess the positioning of NGTs with moderate accuracy, but below the 100 % level required for this safety-critical task. For a radiographer-led NGT radiographic evaluation service to be safe and effective investment in staff training is required. A bespoke training package which includes teaching on image quality, strategies for the identification of poorly-visualised tube tips, and assessment of tube positioning using the NPSA four criteria, should be devised. Further studies will be required following deployment of any training package to assess the efficacy of the training and to confirm that the required standard has been attained.

Data statement

The anonymised dataset may be provided on written request to the corresponding author.

Conflict of interest statement

Andy Creeden – No conflicts of interest to declare.
 Dr Sonyia McFadden – No conflicts of interest to declare.
 Dr Clare Rainey – No conflicts of interest to declare.
 Shaunagh Campbell – Travel grant: Qure.ai Technologies.
 Dr Sarim Ather – Shareholder: RAIQC Ltd.

Dr Ashcaan Hajilou – Travel grant: Qure.ai Technologies.
 Prof Raymond Bond – No conflicts of interest to declare.
 Dr Patrick McAllister – No conflicts of interest to declare.
 Dr Nick Woznitza – Consultancy fees: InHealth, SM Radiology;
 Speakers fees: AstraZenica; Travel grant: Qure.ai Technologies.

Acknowledgements

Sincere thanks to Ben Cooper (University College London Hospitals NHS Foundation Trust) and Dr Paul Lockwood (Canterbury Christchurch University) for their support with data collection, and to RAIQC for use of the RAIQC clinical simulation platform.

This research did not receive any specific grant from funding agencies in the public, commercial, or not-for-profit sectors.

This study was supported by the European Federation of Radiographer Societies, together with the European Society of Radiology, through the EFRS Research Hub at ECR 2023.

References

1. Healthcare Safety Investigation Branch. *Placement of nasogastric tubes*. I2019/006. Retrieved from. 2020. <https://www.hssib.org.uk/patient-safety-investigations/placement-of-nasogastric-tubes/investigation-report/>.
2. Koopmann MC, Kudsk KA, Sztokowski MJ, Rees SM. A team-based protocol and electromagnetic technology eliminate feeding tube placement complications. *Ann Surg* 2011;**253**(2):297–302.
3. Smithard DG, Irizar H. Delays in the placement of nasogastric Tube: where are they? *J Gastroenterol Hepatology Res* 2018;**3**:15.
4. Lamont T, Beaumont C, Fayaz A, Healey F, Huehns T, Law R, et al. Checking placement of nasogastric feeding tubes in adults (interpretation of x ray images): summary of a safety report from the National Patient Safety Agency. *BMJ* 2011;**342**:d2586.
5. NHS England. *Revised never Events policy and framework*. 2018. Retrieved from: <https://www.england.nhs.uk/patient-safety/patient-safety-insight/revised-never-events-policy-and-framework/>.
6. Jones B, Relph W, Small M, Colby J, Taylor S, Cartwright A, et al. *A position paper on nasogastric tube safety: "Time to put patient safety first"*. 2020. Retrieved from: <https://www.bapen.org.uk/pdfs/ngsig/a-position-paper-on-nasogastric-tube-safety-v2.pdf>.
7. NHS England. Placement devices for nasogastric tube insertion DO NOT replace initial position checks. *Patient Safety Alert* 2013. NHS/PSA/W/2013/001. Retrieved from: <https://www.england.nhs.uk/wp-content/uploads/2013/12/psa-ng-tube.pdf>.
8. NHS England. Nasogastric tube misplacement: continuing risk of death and severe harm. *Patient Safety Alert* 2016. NHS/PSA/RE/2016/006. Retrieved from: https://www.england.nhs.uk/wp-content/uploads/2019/12/Patient_Safety_Alert_Stage_2_-_NG_tube_resource_set.pdf.
9. NHS England. *Provisional publication of never Events reported as occurring between 1 April 2023 and 31 March 2024*. 2024. Retrieved from: <https://www.england.nhs.uk/wp-content/uploads/2023/07/provisional-never-events-april-23-31-march-24.pdf>.
10. Thieme A, Rajamohan A, Cooper B, Groombridge H, Simister R, Wong B, et al. Challenges for responsible AI design and workflow integration in healthcare: a case study of automatic feeding tube qualification in Radiology. *arXiv preprint* 2024. arXiv:2405.05299.
11. Lee S, Mason E. Competence in confirming correct placement of nasogastric feeding tubes amongst FY1 doctors. *BMJ Quality Improvement Reports* 2013;**2**(1). u201014. w1198.
12. Roberts S, Theis V, Clark K. Chest x-ray interpretation for nasogastric tube position confirmation: a standardised training module and competency assessment (PWE-105). *Gut* 2019;**68**(Suppl 2):A1–269.
13. Hamdaoui D, Ashworth J, Thompson JD. A scoping review of clinical practices and adherence to UK national guidance related to the placement and position confirmation of adult nasogastric feeding tubes. *Radiography* 2023;**29**(1): 178–83.
14. Keyte E, Roe G, Jeanes A, Kraft JK. Immediate chest radiograph interpretation by radiographers improves patient safety related to nasogastric feeding tube placement in children. *Pediatr Radiol* 2021;**51**(9):1621–5.
15. Roe G, Lambie H, Hood A, Tolan D. Acceptability of a new practice development for radiographers focussed on reducing 'never events' related to nasogastric feeding tubes in adult patients. *Radiography* 2019;**25**(3):235–40.
16. Roe G, Harris KM, Lambie H, Tolan D. Radiographer workforce role expansion to improve patient safety related to nasogastric tube placement for feeding in adults. *Clin Radiol* 2017;**72**(6):518. e1–e518. e7.
17. Posthumus R, Murray M, Gillan C. Considering the role of medical radiation technologists to mitigate the care delivery problems associated with nasogastric tube verification and improve patient care. *J Med Imag Radiat Sci* 2023;**54**(2):291–7.

18. The Royal College of Radiologists. *Radiographer led nasogastric tube position check pathway*. 2024. Retrieved from: <https://www.rcr.ac.uk/news-policy/latest-updates/radiographer-led-nasogastric-tube-position-check-pathway/>.
19. NHS England. *eLearning for healthcare – clinical imaging*. 2024. Retrieved from: <https://www.e-lfh.org.uk/programmes/clinical-imaging/>.
20. Law R. Radiographers, 'never events' and the nasogastric tube. *Radiography* 2014;**20**(1):2–3.
21. College of Radiographers. *Diagnostic radiography workforce UK census 2022*. 2024. Retrieved from: <https://www.sor.org/getmedia/6994cd5d-0155-4a7e-a8a7-32a9bbda81c3/Diagnostic-Radiography-Workforce-UK-Census-2022-report.pdf>.
22. The Royal College of Radiologists. *Clinical Radiology workforce census 2023*. 2023. Retrieved from: <https://www.rcr.ac.uk/media/5befglss/rcr-census-clinical-radiology-workforce-census-2023.pdf>.
23. Pandas, "Pandas" [Online]. Available: <https://pandas.pydata.org/>. [Accessed 14 June 2024].
24. Matplotlib, "Matplotlib" [Online]. Available: <https://matplotlib.org/>. [Accessed 14 June 2024].
25. Shapely, "shapely" [Online]. Available: <https://shapely.readthedocs.io/>. [Accessed 14 June 2024].
26. Drozdov I, Dixon R, Szubert B, Dunn J, Green D, Hall N, et al. An artificial neural network for nasogastric tube position decision support. *Radiology: Artif Intell* 2023;**5**(2):e220165.
27. Chew C, O'Dwyer PJ, Young D, Banziger C, Hope S, Rodolfo S, et al. Mal-positioned nasogastric feeding tubes: are medical students safe to identify them? *Br J Radiol* 2024;**97**(1155):640–5.
28. Kamel T, Sauvage B, Lakhil K, Ottavy G, Janssen-Langenstein R, Jacquier M, et al. The accuracy of intensive care nurses' interpretation of chest radiographs to recognise misplacement of endotracheal and nasogastric tubes after a single training session and comparison with residents' interpretation. *Aust Crit Care* 2023;**36**(6):948–54.
29. Snaith B, Flintham K. Radiology responsibilities post NPSA guidelines for nasogastric tube insertion: a single centre review. *Radiography* 2015;**21**(1):11–5.
30. Torsy T, Saman R, Boeykens K, Eriksson M, Verhaeghe S, Beeckman D. Factors associated with insufficient nasogastric tube visibility on X-ray: a retrospective analysis. *Eur Radiol* 2021;**31**:2444–50.
31. Hazel Rollins C. How accurate are X-rays to check NG tube positioning? *Nurs Times* 2012;**108**(42):14–6.
32. Torsy T, Saman R, Boeykens K, Duysburgh I, Van Damme N, Beeckman D. Comparison of two methods for estimating the tip position of a nasogastric feeding tube: a randomized controlled trial. *Nutr Clin Pract* 2018;**33**(6):843–50.
33. Taylor S, Manara AR. X-ray checks of NG tube position: a case for guided tube placement. *Br J Radiol* 2021;**94**(1124).
34. NHS England. *Resource set - initial placement checks for nasogastric and orogastric tubes*. 2016. Retrieved from: https://www.england.nhs.uk/wp-content/uploads/2016/07/Resource_set_-_Initial_placement_checks_for_NG_tubes_1.pdf.
35. Bhakta P, Keady T, O'Brien B. Nasogastric tube location: a diagnostic dilemma. *Can J Anesth* 2018;**65**:839–40.
36. Lio J, Wu F, Chuang P. Feasibility of nasogastric tube feeding into type III hiatal hernia. *AJG* 2018;**113**:S1688.
37. Gur D, Bandos AI, Cohen CS, Hakim CM, Hardesty LA, Ganott MA, et al. The "laboratory" effect: comparing radiologists' performance and variability during prospective clinical and laboratory mammography interpretations. *Radiology* 2008;**249**(1):47–53.