

DE NOVO STONE FORMATION IN URETERIC STUMP POST-NEPHRECTOMY

Ahmed Mohamed*, Omer Abdalla, Banan Omer, Sanjeev Madaan, Seshadri Sriprasad

Dartford and Gravesham NHS Trust, Department of Urology, Dartford, UK

Correspondence author: ahmed.mohamed35@nhs.net

Abstract

Introduction: The leftover ureteric stump after a simple nephrectomy is rarely symptomatic. Here, we report a unique case of ureteric stump stones that likely developed de novo and patients became symptomatic.

Case Report: We report the case of a 53-year-old female, who had benign right nephrectomy for a non-functioning kidney 17 years ago and presented with three years history of recurrent urinary tract infections and right-side abdominal pain. A continuous unenhanced computed tomography scan confirmed the presence of multiple de novo stones in the leftover ureteric stump, which was successfully treated by an open transperitoneal ureteric stumpectomy. She was asymptomatic at 12 months post-operative follow-up. We describe problems of leftover ureteric stumps and the possible pathophysiology of the stones formation in this group of patients.

Conclusion: Albeit rare, various symptoms and complications can develop in the leftover stump, including stumpitis, urinary tract infections, and calculi. Therefore, discussion with patients of ureteric stump complications is recommended.

Keywords: *nephrectomy, ureteric stump stones, urolithiasis*

INTRODUCTION

A complete ureterectomy is rarely performed with benign (non-cancer) nephrectomy, and leaving a ureteric stump is usually asymptomatic.¹ Complications of the retained ureteric stump are rare and include recurrent urinary tract infections (UTIs), vesicoureteric reflux, stump empyema, stumpitis mimicking pyelonephritis, tumors and stone formations within the stump.¹⁻⁴

Here, we report a unique case of a likely de novo ureteric stump stones, complicating leftover ureteric stump following a failed Boari flap ureteric implantation, which to our knowledge, is the first case to be reported.

CASE PRESENTATION

A 53-year-old lady presented with a three years history of culture-proven recurrent UTIs and right-sided abdominal pain. Her medical history was significant as she had a laparotomy for ectopic pregnancy when she was 21, followed by two subsequent caesarean sections. A few years later, she was found to have right distal ureteric stricture, probably due to her previous pelvic surgeries. She underwent Boari flap ureteric reconstruction, which had failed, leading to a non-functioning kidney and subsequently underwent benign open nephrectomy and left the ureteric stump behind. On examination, her abdomen was soft and not tender. Urine cultures grew

E coli on several occasions, which was sensitive to nitrofurantoin and Trimethoprim. In one instance, the causative organism of her UTI was staphylococcus Saprophyticus which was again sensitive to the same antibiotics. A computerized tomographic (CT) scan was then organized to investigate her further; this showed multiple radiopaque calculi within the right ureteric stump (Figures 1 and 2), which was presumed to be the cause of her symptoms.

Interestingly, intravenous urography (IVU) performed before the nephrectomy did not report stones or filling defects. Furthermore, an interval CT scan performed 4 years following the nephrectomy to

investigate left-sided abdominal pain and vomiting showed no ureteric calculi or a cause of her symptoms. Initial conservative management with oral antibiotics did not improve her condition. This case was discussed in the stone multi-disciplinary team meeting, and the decision was made to treat stones with laser lithotripsy. An attempt of endoscopic removal of stones with rigid ureteroscopy was unsuccessful due to ureteric orifice stenosis and the inability to pass a guide wire into the right ureteric stump. Endoscopic right intramural ureterotomy was carried out, and a 14 Fr urinary catheter was inserted. She then underwent an open transperitoneal right

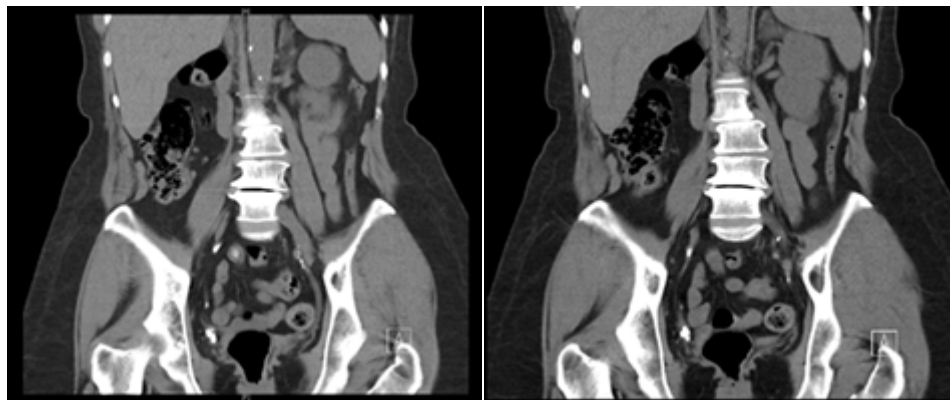


FIGURE 1 Unenhanced computed tomography showing multiple calculi with in right ureteric stump.

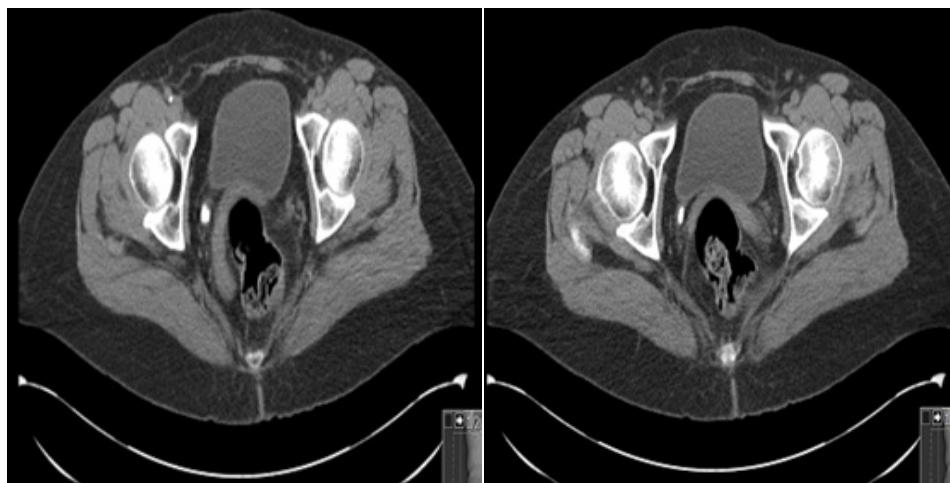


FIGURE 2 Cross-sectional unenhanced computed tomography showing right ureteric stump stones.

stumpectomy (Figures 3 and 4) in the same sitting. Using x-ray guidance and an artery clip, the ureteric stump with contained calculi was identified, and the overlying skin was marked. A limited hockey-stick incision was made in the right lower quadrant, and the abdomen opened in layers with the right external iliac artery used for anatomical correlation and the right ureteric stump was then identified, this was confirmed by palpating the stones and also tracking distal course to the bladder. The stump was then dissected carefully and excised with its intramural part. A urinary catheter was removed after two weeks. The specimen measured 10 cm in length with

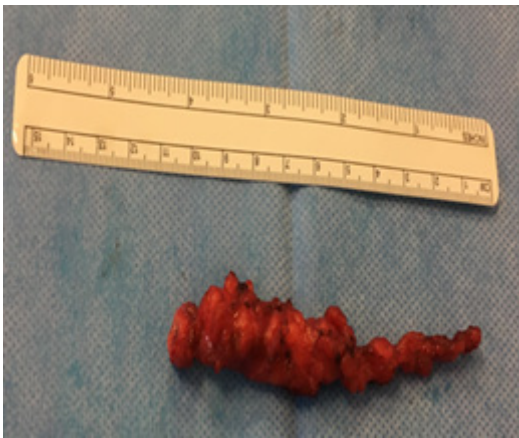

FIGURE 3 Image showing a 10-cm right ureteric stump specimen with dilated proximal end.




FIGURE 4 Fluoroscopy confirming presence of stone inside ureteric stump specimen.

dilated proximal end measuring 10 mm in diameter (Figure 3). The histology showed dense chronic inflammatory cell infiltrate, squamous metaplasia of the urothelium in the proximal part, and no evidence of malignancy or suture material. The patient made an uneventful recovery, and all her symptoms resolved.

DISCUSSION

Benign nephrectomy for non-cancer conditions is usually carried out without excision of the whole ureter.¹ The complications of the retained ureteric stump are rare and include recurrent UTIs, stumpitis mimicking pyelonephritis, vesicoureteral reflux, stump empyema, tumors, and stone formations within the stump.¹⁻⁴

Developing stones in the leftover ureteric stump is even more uncommon, with an incidence of less than 1%.¹ Ureteric stump calculi, albeit rare, have been reported mainly in patients with urolithiasis leading to nephrectomy.⁵⁻⁸ Praisner et al. and Maegawa et al. reported two cases of ureteric stump empyema due to obstructing stone in patients known to have ureteric stones before nephrectomy.^{5,7} Russinko PJ et al. reported ureteric stump calculi in a patient with augmentation enterocystoplasty, which was treated successfully with ureteroscopy and laser ablation.⁹ Donkelaar et al. reported a case of ureteric stump stone in a patient with systemic lupus erythematosus (SLE) with no previous history of urolithiasis or vesicoureteral reflux (VUR) who underwent bilateral nephrectomy due to non-functioning kidneys, but no confirmatory pre-nephrectomies or interval scans performed, further SLE is frequently associated with renal tubular acidosis and hyperuricemia which predispose to urolithiasis.¹⁰ However, this case is unique in that the stones were likely developed *de novo*, since the patient had no history of renal stones or predisposing morbidity before nephrectomy, and both IVU (pre-nephrectomy) and interval CT (post-nephrectomy) scans did not reveal calculi; however later scan showed radiopaque stones (Figures 1 and 2).

Naegu et al. postulated that several factors may play a role in the pathophysiology of ureteral

stump disease, such as distal obstruction (stenosis or stone), urine stasis secondary to hypotonia or atonia, damage of ureteral blood vessels and neural plexus, VUR. Pre-existing or concurrent inflammation around the residual ureter.¹¹ Rose et al. and others suggested that reflux of urine into the blind stump may act as a diverticulum with consequent poor urine drainage and recurrent UTIs, which have an essential role in the formation of calculi.^{8,9}

In their case report, Ten Donkelaar et al. noted that the narrow ureteric stump orifice may have been predisposed to stasis with consequent UTIs and stone formation.¹¹ Similarly, in our case, there was ureteric ostium stenosis preventing catheterization with a guide wire, furthermore, the dilated proximal end of the stump may suggest VUR. Therefore, we postulate that initial VUR with recurrent infections and repeated inflammations of the stump (stumpitis) probably led to stump stenosis, resulting in urinary stasis and the formation of stones.

The treatment options for symptomatic ureteric stump calculi include endoscopic management through stumposcopy with laser ablation, and open or laparoscopic excision of the ureteric stump if endoscopic management is unsuccessful. Russinko PJ et al. and Ten Donkelaar et al. reported successful treatment of ureteric stump stones with holmium-laser lithotripsy using rigid and flexible ureteroscopy, respectively.^{9,10} Rose et al. reported successful open extraperitoneal ureterectomy in two cases. At the same time, Weiland et al. successfully removed a ureteric stump with contained stones via a transperitoneal laparoscopic approach. However, two additional ports were used, and the intramural part was left behind.^{6,8} In our case, endoscopic management was unsuccessful due to distal stump stenosis, since the guide wire failed to pass beyond the stenotic ostium, and a laparoscopic excision was not considered due to multiple previous operations and abdominal scarring. Therefore, it was prudent to proceed with an open ureteric stumpectomy carried out successfully with no complications.

CONCLUSION

Although rare, various symptoms and complications can develop in leftover stumps, including stumpitis, UTIs, and calculi. Recurrent UTIs appear to be the most common presentation of the leftover ureteric stump in post-nephrectomy patients, as the stump acts as a diverticulum harboring infections. One must bear in mind the residual ureteric stump complications in patients with non-specific symptoms after benign nephrectomy. Therefore, consideration of nephroureterectomy rather than standalone nephrectomy is advisable in selected cases such as patients with evidence of VUR, known stone formers, and those with urolithiasis predisposing factors. If feasible, endoscopic management of ureteric stump stones should be attempted first.

REFERENCES

1. Malek RS, Moghaddam A, Furlow WL, Green LF. Symptomatic ureteral stumps. *J Urol.* 1971;106:521–8. [https://doi.org/10.1016/s0022-5347\(17\)61332-6](https://doi.org/10.1016/s0022-5347(17)61332-6)
2. Ikeda D, Matsutani R, Fukuda M, Fuse H, Hirano S. Transurethral fulguration for empyema of ectopic ureteral stump. *Int J Urol.* 2003;10(12):664–6. <https://doi.org/10.1046/j.1442-2042.2003.00714.x>
3. Kim YJ, Jeon SH, Huh JS, Chang SG. Long-term follow-up of ureteral stump tumors after nephrectomy for benign renal disease. *Eur Urol.* 2004;46(6):748–52. <https://doi.org/10.1016/j.eururo.2004.07.005>
4. Persad R, Kamineni S, and Mouriquand PD. Recurrent symptoms of urinary tract infection in eight patients with refluxing ureteric stumps. *Br J Urol.* 1994;74:720–22. <https://doi.org/10.1111/j.1464-410x.1994.tb07113.x>
5. Prajsner A, Szewczyk W, Gawron R. Empyema of retained ureteral stump with gross stone 20 years after nephrectomy. *Urology.* 2009;73(5):993–4. <https://doi.org/10.1016/j.urology.2008.12.003>
6. Weiland D, Canales B, Ramani A, Monga M. Laparoscopic ureterectomy for the management of painful calculi in a ureteral stump. *Int J Urol.* 2005;12(9):845–6. <https://doi.org/10.1111/j.1442-2042.2005.01168.x>
7. Maegawa M, Kitamura K, Usida H, et al. Empyema of the ureteral stump with multiple stones after nephrectomy. *Hinyokika Kyo.* 2002 Mar;48(3):167–9.

8. Rose RH, Heyman J, Grabstald H. Ureteral stump calculi. *Urology*. 1990;35:527–9. [https://doi.org/10.1016/0090-4295\(90\)80109-z](https://doi.org/10.1016/0090-4295(90)80109-z)
9. Russinko PJ, Siddiq FM, Zabbo A. A retained ureteral stump with calculi. *J Urol*. 2003;169(1):268. <https://doi.org/10.1097/01.ju.0000039544.04755.8b>
10. Ten Donkelaar CS, Wortel RC, Lock MTWT. Rare case of urinary tract infections and the “forgotten” solution. *Scand J Urol*. 2015. <https://doi.org/10.3109/21681805.2015.1063082>
11. Neagu V, Ioanid C, Angelescu N. Disorders of the ureteral stump. *Int Urol. Nephrol*. 1971;5:363.